



We Won!

We are delighted to announce that we have been awarded the Macedon Ranges Business Award for Excellence in Professional Services for 2009. I would like to personally extend a BIG thank you to all our clients and supporters. The award recognises innovation, development and quality and I hope that these are qualities we continue to provide.



Dr Lee named Young Business Person of the Year

Again a big thank you to all our clients and supporters!




Advanced Equine Dentistry now CVAMA accredited.

This accreditation means that Shannon has exceeded 120 continuing education points, and this has been recognised by the **Australian Veterinary Association**. You can be confident that we continue to work hard to stay update with the latest information, equipment and techniques.

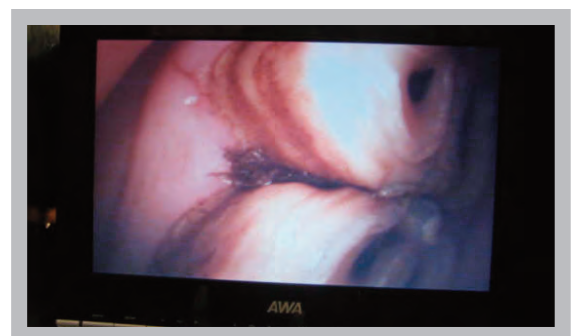
New Developments — equine dental equipment

Intra oral camera

At Advanced Equine Dentistry we have pioneered some of the biggest advances in equine dental care of the past several decades, and as some of you will be aware we have been working with a number of companies to develop an **intraoral dental system suitable for use in horses**. Following on from our work with the **snake eye camera** we told you about last time (video of which can be viewed on our website — **see Intraoral Video under Services & Equipment**), we recently tested a new system. This system incorporating a camera and video screen allows us to show inside your horse's mouth like never before. If you thought those teeth looked big, imagine what they look like when each one is magnified on a 30cm screen. We are very excited about this device both from a diagnostics point of view and as a teaching aid.



The Intraoral Video system in action



The snake eye camera view on screen

New X-ray Equipment Arrives

We are pleased to announce the purchase of new Xray equipment. This equipment is currently being installed and we will be ready to take Xrays in the next few weeks.



Enter our competition and WIN!
We've got new number plates! Can you figure it out?



If so simply email your answer to info@advancedequinedentistry.com.au TOO HARD? simply go to our website at www.advancedequinedentistry.com.au and click **contact us**. All correct entries go in the draw for a prize so don't forget to include your contact details — GOOD LUCK!

Shannon performs emergency fillings

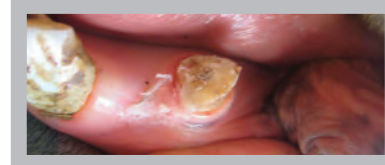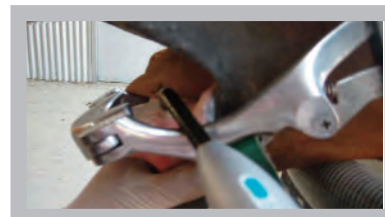
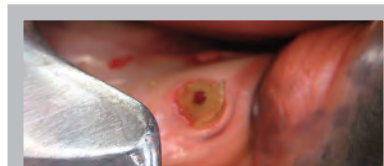
A couple of recent cases have highlighted something that **ALL horse owners should be aware of**. All of these horses had fractured a tooth leading to exposure of the vital pulp — this is the tissue that contains the nerve and blood supply to the tooth. Without it the tooth will die and a painful abscess will occur over the tooth root. Some of you may have had root canal therapy and can no doubt relate to what I am saying. In recent cases of pulp exposure like these it is possible to perform a procedure to remove some of the pulp and insert a filling to protect the rest from death. So if you suspect trauma to the mouth, remember this procedure must be performed **within the first 48hrs to protect the tooth**. If someone is performing dentistry they must have the knowledge and equipment to perform this — **don't worry, WE DO!**

Left from top:

Fractured tooth with visible pulp (nerve)


Curing dental material with light

Tooth after pulp capping and filling




Patient Profile: Recent Case of a Real Headache


This case came to AED recently. The mare was in a great of discomfort due to a tooth root abscess, which had lead to a sinusitis (an inflamed sinus cavity full of pus!). She had lost a lot of weight and required extraction of two teeth and surgery of the sinus. Her appetite has returned and we will check back on her in a few months to see how she is going.



Mare on arrival at AED



Sinus surgery



Flush tube to keep sinus clear